



Available online on 15.07.2017 at <http://ujpr.org>

Universal Journal of Pharmaceutical Research

An International Peer Reviewed Journal

Open access to Pharmaceutical research

© 2017, publisher and licensee UJPR, This is an open access article which permits unrestricted non commercial use, provided the original work is properly cited

Volume 2, Issue 3, 2017

REVIEW ARTICLE

GLAUCOMA: SECRETS OF SILENT THIEF OF VISION- A REVIEW

Oyeniran Taiwo Opeyemi

Department of Biochemistry, University of Ibadan, Nigeria.

*Corresponding Author's Email: tinwoye2011@gmail.com

DOI: <http://doi.org/10.22270/ujpr.v2i3.RW3>

Received 2 June 2017; Revised 6 July; Accepted 9 July, Available online 15 July 2017

ABSTRACT

Glaucoma has been highlighted as a priority eye disease by the World Health Organization's global initiative to eliminate avoidable blindness by the year 2020. Glaucoma is defined as an optic neuropathy, characterized for loss of visual field and injury of the optic nerve. However the mechanism leading to the disease is still unclear. Factors that are responsible for it include glutamate-induced neurotoxicity, nitric oxide based damage, disruption of neurotrophic factor transport and immune-induced neuro destruction. At present treatment options primarily aim at decreasing intra-ocular pressure (IOP) by utilizing pharmacological agents, laser therapy and surgery. Gaining a better understanding of the pathogenesis can aid in the development of new treatment options and, perhaps, even a cure for glaucoma. Since there is no cure for Glaucoma, early detection and treatment can slow or prevent further vision loss. This article discusses the pathophysiology of glaucoma, its detection, diagnosis monitoring and treatment.

Keywords: Glaucoma, glutamate-induced neurotoxicity, intra-ocular pressure, neuropathy.

INTRODUCTION

The glaucoma is defined, currently, as an optic neuropathy, characterized for loss of visual field and injury of the optic nerve, being the increase of the intra-ocular pressure (IOP) considered as a risk factor. In glaucoma, the eye's drainage system becomes clogged so the intraocular fluid cannot drain¹. As the fluid builds up, it causes pressure to build inside the eye. High pressure damages the sensitive optic nerve and results in vision loss².

Glaucoma is not a single clinical entity but a group of ocular diseases with various causes that ultimately are associated with a progressive optic neuropathy leading to loss of vision.

At present 8.4 million persons worldwide are bilaterally blind as a result of glaucoma (4,472,083 open angle glaucoma (OAG) and 3,936,241 angle closure glaucoma (ACG). Glaucoma is the second worldwide cause of blindness, making it the second leading cause of bilateral blindness. Glaucoma is termed as "silent thief of sight", the blindness caused by this disease is irreversible.

Glaucoma affects people of all ages, from babies to older adults³. Although everyone is at risk for glaucoma, those at higher risk include people over age 60, relatives of people with glaucoma, people of African descent, people with diabetes, people with extensive use of steroids, and people who have elevated eye pressure⁴.

Sight loss resulting from glaucoma cannot be reversed. However, early detection and careful, lifelong

treatment with medication or surgery can maintain vision⁵.

In the most common form of glaucoma, buildup of fluid pressure happens very slowly. Often, there are no uncomfortable or painful symptoms and can suddenly result in vision loss.

Structure of the Eye ball

The eye is our organ of sight. It is not shaped like a perfect sphere, composed of the anterior segment and the posterior segment. The anterior segment is made up of the cornea, iris and lens⁶.

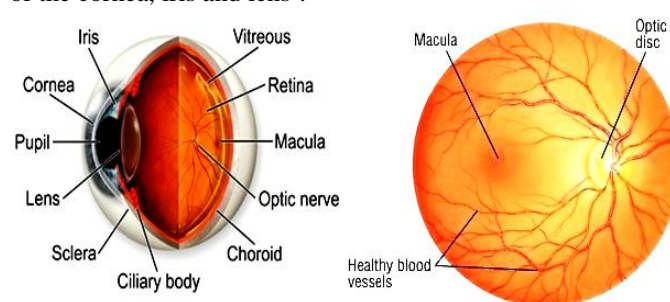


Figure 1: Normal eye anatomy

Cornea: The cornea is transparent and more curved, and is linked to the larger posterior segment, composed of the vitreous, retina, choroid and the outer white shell called the sclera, clear front window of the eye that transmits and focuses light into the eye. The cornea is typically about 11.5 mm (0.3 in) in diameter, and 1/2 mm (500 um) in thickness near its center⁷.

Iris: colored part of the eye that helps regulate the amount of light that enters. The iris is the pigmented

circular structure concentrically surrounding the center of the eye, the pupil, which appears to be black. The iris of the eye functions like the diaphragm of a camera, controlling the amount of light reaching the back of the eye by automatically adjusting the size of the pupil⁸.

Pupil: dark aperture in the iris that determines how much light is let into the eye. The size of the pupil, which controls the amount of light entering the eye, is adjusted by the iris' dilator and sphincter muscles. After passing through the cornea, light travels through the pupil (the black dot in the middle of the eye)⁹.

Lens: transparent structure inside the eye that focuses light rays onto the retina. Behind the iris sits the lens. By changing its shape, the lens focuses light onto the retina. Through the action of small muscles (called the ciliary muscles), the lens becomes thicker to focus on nearby objects and thinner to focus on distant objects¹⁰.

Retina: nerve layer that lines the back of the eye, senses light, and creates electrical impulses that travel through the optic nerve to the brain. The retina contains the cells that sense light (photoreceptors) and the blood vessels that nourish them¹¹.

Macula: The most sensitive part of the retina is a small area called the macula, which has millions of tightly packed photoreceptors (the type called cones). The high density of cones in the macula makes the visual image detailed, just as a high-resolution digital camera has more megapixels¹².

Optic nerve: connects the eye to the brain and carries the electrical impulses formed by the retina

to the visual cortex of the brain. The photoreceptors in the retina convert the image into electrical signals, which are carried to the brain by the optic nerve¹³.

Each photoreceptor is linked to a nerve fiber. The nerve fibers from the photoreceptors are bundled together to form the optic nerve. The optic disk, the first part of the optic nerve, is at the back of the eye.

There are two main types of photoreceptors: cones and rods.

i). Cones are responsible for sharp, detailed central vision and color vision and are clustered mainly in the macula¹⁴.

ii). Rods are responsible for night and peripheral (side) vision. Rods are more numerous than cones and much more sensitive to light, but they do not register color or contribute to detailed central vision as the cones do. Rods are grouped mainly in the peripheral areas of the retina¹⁵.

Vitreous: clear, jelly-like substance that fills the middle of the eye¹⁶.

TYPES OF GLAUCOMA

Glaucoma can be classified according to anterior chamber angle findings and the presence or absence of disease (states) causing elevated IOP and accompanying factors. Different types of glaucoma are identified, that is generally classified into open angle or angle closure glaucoma based on the width of the angle between the cornea and the iris¹⁷.

Open-Angle Glaucoma

Open-angle glaucoma, the most common form of glaucoma, accounting for at least 90% of all glaucoma

cases: is caused by the slow clogging of the drainage canals, resulting in increased eye pressure has a wide and open angle between the iris and cornea develops slowly and is a lifelong condition has symptoms and damage that are not noticed¹¹.

There are no early warning signs of open-angle glaucoma (also called primary or chronic glaucoma). It develops slowly and sometimes without noticeable sight loss for many years¹⁸. Most people who have open-angle glaucoma feel fine and do not notice a change in their vision. That is why regular eye exams are so important. With early detection, open-angle glaucoma usually responds well to medication. However, it will be very important that you carefully follow your medication regimen to continually preserve healthy eye pressure and prevent vision loss¹⁹.

Angle-Closure Glaucoma

The other main type of glaucoma is called angle-closure glaucoma. It is also called acute glaucoma or narrow-angle glaucoma. This type is rare and: is caused by blocked drainage canals, resulting in a sudden rise in intraocular pressure has a closed or narrow angle between the iris and cornea develops very quickly has symptoms and damage that are usually very noticeable demands immediate medical attention²⁰. The closed angle prevents fluid from reaching the drainage canals. As a result, the intraocular pressure rises very quickly, causing a painful attack in the eye. The eye may appear red. Treatment of angle-closure glaucoma usually involves either laser or conventional surgery to remove a small portion of the bunched-up outer edge of the iris. Surgery helps unblock the drainage canals so that the extra fluids can drain²¹.

Other types of Glaucoma

Most of the other types of glaucoma are variations of open-angle or angle-closure types. These types can occur in one or both of your eyes²².

Secondary Glaucoma

It can occur as the result of an eye injury, inflammation, tumor, in advanced cases of cataract or diabetes or by certain drugs such as steroids. This form of glaucoma may be mild or severe²³.

Pigmentary Glaucoma

Is a form of secondary open-angle glaucoma, occurring when the pigment granules that are in the back of the iris (the colored part of the eye) break into the clear fluid produced inside the eye. These tiny pigment granules flow toward the drainage canals in the eye and slowly clog them, causing eye pressure to rise. Treatment usually includes medications, laser surgery, or filtering surgery²⁴.

Normal-tension Glaucoma (NTG)

It is also called low-tension or normal-pressure glaucoma. In this type of glaucoma, the optic nerve is damaged even though the intraocular pressure is not very high. The cause is unknown. People at higher risk for normal tension glaucoma have a family history of normal-tension glaucoma, are of Japanese ancestry, or have a history of systemic heart disease, such as irregular heart rhythm²⁵.

Congenital Glaucoma

Occurs in babies when there's incorrect or incomplete development of the eye's drainage canals during the

prenatal period. This is a rare condition that may be inherited. Exfoliative Glaucoma occurs when a flaky, dandruff-like material peels off the outer layer of the lens within the eye. The material collects in the angle between the cornea and iris and can clog the drainage system of the eye, causing eye pressure to rise²⁶.

Congenital glaucoma can often be corrected with microsurgery.

Neovascular Glaucoma

The abnormal formation of new blood vessels on the iris and over the eye's drainage channels can cause this form of open-angle glaucoma. Neovascular glaucoma is always associated with other abnormalities, most often diabetes. It never occurs on its own. The new blood vessels block the eye's fluid from exiting through the trabecular meshwork (the eye's drainage canals), causing an increase in eye pressure²⁷.

Uveitic Glaucoma

Uveitis is swelling and inflammation of the uvea, the middle layer of the eye. The uvea provides most of the blood supply to the retina. Increased eye pressure in uveitis can result from the inflammatory process itself or the medication (steroids) used to treat it²⁸.

Traumatic Glaucoma

Injury to the eye may cause traumatic glaucoma. This form of open-angle glaucoma can occur immediately after the injury or develop years later. It can be caused by blunt injuries that bruise the eye (called blunt trauma) or by injuries that penetrate the eye²⁹.

DIAGNOSIS

In less common kinds of glaucoma, symptoms can be more severe. These symptoms can include:

- Hazy vision.
- The appearance of rainbow-colored circles around bright lights.
- Sudden sight loss.
- Eye and head pain
- Nausea or vomiting.

To be safe and accurate, following diagnostic exams should be used for glaucoma diagnosis:

1. **Tonometry**- The inner eye pressure (IOP)³⁰.
2. **Ophthalmoscopy or dilated eye exam**- The shape and color of the optic nerve.
3. **Perimetry test**- The complete field of vision.
4. **Gonioscopy**- The angle in the eye where the iris meets the cornea³¹.
5. **Pachymetry**- Thickness of the cornea.

It is also important to interview the patient concerning subjective symptoms, with symptoms such as blurred vision, irisopsia, eye pain, headache, and hyperemia indicating a possible history of acute glaucoma attacks. Patient's family history and patients with a family history of glaucoma in particular should be asked about visual function damage in blood relatives³².

TREATMENT

The purpose of glaucoma therapy at the present time is to maintain the patient's visual function. At present, based on the evidence, the only reliable treatment for glaucoma is to decrease IOP. Improvement of ocular blood flow and direct neuroprotection have attracted attention as new therapeutic methods involving factors

other than IOP, and these may become innovative therapeutic options in the future.

- Medication
- Laser use and surgery

Medication

Eye drops

Glaucoma treatment often starts with eye drops. These can help decrease eye pressure by improving fluid drains from eye³³. Prescription eye drop medications include-

i. Prostaglandins. These increase the outflow of the fluid in eye and reduce pressure³⁴.

Examples- latanoprost (Xalatan) and bimatoprost (Lumigan).

Side effects- mild reddening and stinging of the eyes, darkening of the iris, changes in the pigment of the eyelashes or eyelid skin, and blurred vision.

ii. Beta blockers. These reduce the production of fluid in eye, thereby lowering the pressure in eye³⁵.

Examples- timolol and betaxolol.

Side effects- difficulty breathing, slowed heart rate, lower blood pressure, impotence and fatigue.

iii. Alpha-adrenergic agonists. These reduce the production of aqueous humor and increase outflow of the fluid in eye³⁶.

Examples- apraclonidine (Iopidine) and brimonidine (Alphagan).

Side effects- an irregular heart rate; high blood pressure; fatigue; red, itchy or swollen eyes; and dry mouth.

iv. Carbonic anhydrase inhibitors. Rarely used for glaucoma, these drugs may reduce the production of fluid in eye³⁷.

Examples- dorzolamide (Trusopt) and brinzolamide (Azopt).

Side effects- metallic taste, frequent urination, and tingling in the fingers and toes.

v. Miotic or cholinergic agents. These increase the outflow of fluid from eye³⁸.

Example- pilocarpine.

Side effects- smaller pupils, possible blurred or dim vision, and nearsightedness.

Oral medications

If eyedrops alone don't bring eye pressure down to the desired level, usually a carbonic anhydrase inhibitors are prescribed as an oral medication. Possible side effects include frequent urination, tingling in the fingers and toes, depression, stomach upset, and kidney stones³⁹.

Laser use and surgery

Other treatment options include laser therapy and various surgical procedures. Possible complications include pain, redness, infection, inflammation, bleeding, abnormally high or low eye pressure, and loss of vision. Some types of eye surgery may speed the development of cataracts. Surgery is the main treatment method for angle-closure glaucoma and congenital glaucoma, because it may be the only way that the blocked or incorrectly formed drainage canals can be opened. In cases of open-angle glaucoma, surgery is usually considered when the maximum amount of medication is not controlling eye pressure or when patient cannot tolerate the side effects of the

medication. The primary strategy involves “burning” holes in various areas within the eyes including the ciliary and the pigmented trabecular meshwork cells. The benefits include being noninvasive, needing less patient compliance and lowering the possibility of infection or bleeding⁴⁰.

Types of laser surgery

1. Argon Laser Trabeculoplasty (ALT)

Used for primary open-angle glaucoma. Laser beam is aimed at the fluid drainage channels helping the drainage system work⁴¹.

2. Selective Laser Trabeculoplasty (SLT)

Uses a laser that works at very low levels. Treats specific cells and leaves the mesh-like drainage canals surrounding the iris intact. Because it affects only certain cells without causing collateral tissue damage, SLT can potentially be repeated⁴².

3. Laser Peripheral Iridotomy (LPI)

LPI is frequently used to treat angle-closure glaucoma, in which the angle between the iris and the cornea is too small and blocks fluid flow out of the eye. A laser creates a small hole in the iris to allow fluid drainage⁴³.

4. Micropulse Laser Trabeculoplasty (MLT)

Provides the same pressure-lowering effects as SLT and ALT. Uses a specific diode laser to deliver laser energy in short microbursts.

5. Laser Cyclophotocoagulation

This procedure is usually used to treat more aggressive or advanced open-angle glaucoma that has not responded to other therapies. Your doctor directs a laser through the sclera or endoscopically at the eye fluid-producing ciliary body. The procedure helps decrease the production of fluid and lower eye pressure. Patients often need multiple treatments⁴⁴.

Incisional surgery

Incisional surgery is use in cases in which sufficient reduction of IOP cannot be achieved by other therapeutic means, or cases in which other appropriate means of treatment cannot be used because of adverse effects or non-compliance, and cases in which it is thought that sufficient reduction of IOP cannot be achieved by other therapeutic means.

The indication for surgery must be made for each individual patient based on a comprehensive assessment of type of glaucoma, stage of glaucoma, the patient’s disease awareness, compliance, and the patient’s social background⁴⁴.

CONCLUSION

Glaucoma is significant public health challenge because it is irreversible. The therapies available for glaucoma can prevent or slow vision loss, but once vision has been lost it cannot be restored. Early diagnosis and treatment can prevent vision loss from the disease.

Treatment options for patients with glaucoma include medications, laser therapy, and incisional surgery. The risks and benefits of each type of treatment must be carefully considered to maximize the treatment’s benefits while minimizing adverse effects. There is need of advances in glaucoma treatment because

proven medical and surgical therapies are limited in their capacity to stop glaucoma progression.

REFERENCES

- Choi J, Jeong J, Ho HS, Kook MS. Effect of nocturnal blood pressure reduction on circadian fluctuation of mean ocular perfusion pressure: a risk factor for normal tension glaucoma. *Investigative Ophthalmology and Visual Science* 2006; 47(3): 831–836.
- Levin LA. Retinal ganglion cells and neuroprotection for glaucoma. *Surv Ophthalmol* 2003; 48: S1-S24.
- Lin SC. Endoscopic and transscleral cyclophotocoagulation for the treatment of refractory glaucoma. *J Glaucoma* 2008; 17: 238-47.
- Chua B, Goldberg I. Neuroprotective agents in glaucoma therapy: Recent developments and future directions. *Expert Rev Ophthalmol* 2010; 5: 627-36.
- Aptel F, Charrel T, Lafon C, Romano F, Chapelon JY, Blumen Ohana E, Nordmann JP, Denis P. Miniaturized high-intensity focused ultrasound device in patients with glaucoma: a clinical pilot study. *Invest Ophthalmol Vis Sci* 2011; 52: 8747-53.
- Song YK, Lee CK, Kim J, Hong S, Kim CY, Seong GJ. Instability of 24-hour intraocular pressure fluctuation in healthy young subjects: a prospective, cross-sectional study. *BMC Ophthalmology* 2014; 127: 2014.
- Pasquale LR, Wiggs JL, Willett WC, Kang JH. The relationship between caffeine and coffee consumption and exfoliation glaucoma or glaucoma suspect: A prospective study in two cohorts. *Invest. Ophthalmol Vis Sci* 2012; 53: 6427-6433.
- Fan BJ, Leung YF, Wang N, Lam SC, Liu Y, Tam OS, Pang CP. Genetic and environmental risk factors for primary open-angle glaucoma. *Chinese Med J* 2004; 117(5): 706-710.
- Engin KN, Yemişci B, Yiğit U, Ağaçhan A, Coşkun C. Variability of serum oxidative stress biomarkers relative to biochemical data and clinical parameters of glaucoma patients. *Mol Vis* 2010; 16: 1260–1271.
- Wishal D, Roger CW, Wolfs JC, Albert HT, Johannes R. Vingerling Nutrient intake and risk of open-angle glaucoma: the Rotterdam Study. *Eur J Epidemiol* 2012; 27(5): 385-393.
- Cordeiro MF, Levin LA. Clinical evidence for neuroprotection. in glaucoma. *Am J Ophthalmol* 2011; 152: 715-6.
- Grieshaber MC, Flammer J. Is the medication used to achieve the target intraocular pressure in glaucoma therapy of relevance-An exemplary analysis on the basis of two beta-blockers. *Prog Ret. Eye Res* 2010; 29: 79-93.
- Stewart WC, Kolker AE, Sharpe ED, Day DG, Holmes KT, Leech JN. Factors associated with long-term progression or stability in primary open-angle glaucoma. *Am J Ophthalmol* 2000; 130: 274-9.
- Chen SJ, Lu P, Zhang W, Lu J. High myopia as a risk factor in primary open angle glaucoma. *Int J Ophthalmol*. 2012; 5(6): 750–753.
- Tan GS, Wong TY, Fong CW, Aung T. Diabetes, metabolic abnormalities, and glaucoma. *Arch Ophthalmol* 2009; 127: 1354–1361.
- Scheer FAJL, Michelson AD, Frelinger AL. The human endogenous circadian system causes greatest platelet activation during the biological morning independent of behaviours. *Plos One* 2011; 6 (9): 245-49.
- Cherecheanu AP, Garhofer G, Schmidl D, Werkmeister R, Schmetterer L. Ocular perfusion pressure and ocular blood flow in glaucoma. *Curr Opin Pharmacol* 2013; 13 (1): 36–42.
- Schmidl D, Garhofer G, Schmetterer L. The complex interaction between ocular perfusion pressure and ocular blood flow- relevance for glaucoma. *Experimental Eye Research* 2011; 93 (2): 141–155.

19. Gazzard G, Friedman DS, Devereux JG, Chew P, Seah SK. A prospective ultrasound biomicroscopy evaluation of changes in anterior segment morphology after laser iridotomy in Asian eyes. *Ophthalmology* 2003; 110: 630–638.
20. Ting JL, Damji KF, Stiles MC. Trabectome Study Group. Ab interno trabeculectomy: Outcomes in exfoliation versus primary open-angle glaucoma. *J Cataract Refract Surg* 2012; 38: 315-23.
21. Spaeth GL, Bernstein P, Caprioli J, Schiffman RM. Control of intraocular pressure and fluctuation with fixed-combination brimonidine-timolol versus brimonidine or timolol monotherapy. *Am J Ophthalmol* 2011; 151: 93-9.
22. Nolan WP, Foster PJ, Devereux JG, Uranchimeg D, Johnson GJ. YAG laser iridotomy treatment for primary angle closure in east Asian eyes. *Br J Ophthalmol* 2000; 84: 1255-1259.
23. Weinreb RN, Toris CB, Gabelt BT, Lindsey JD, Kaufman PL. Effects of prostaglandins on the aqueous humor outflow pathways. *Surv Ophthalmol* 2002; 47: S53–64.
24. Snyder RW, Stamer WD, Kramer TR, Seftor REB. Corticosteroid treatment and trabecular meshwork proteases in cell and organ culture supernatants. *Exp Eye Res* 1993; 57:461–468.
25. Wise LA, Rosenberg L, Radin RG, Mattox C, Yang E.B., A prospective study of diabetes, lifestyle factors, and glaucoma among African-American women. *Ann Epidemiol*. 2011; 21: 430–439.
26. Killer HE, Miller NR, Flammer J, Meyer P, Weinreb RN, Remonda L, Jaggi GP. Cerebrospinal fluid exchange in the optic nerve in normal-tension glaucoma. *Br J Ophthalmol* 2012; 96: 544-8.
27. Wang SY, Singh K, Lin SC. Glaucoma and vitamins A, C, and E supplement intake and serum levels in a population-based sample of the United States. *Eye* 2013; 27: 487–494.
28. Weinreb RN, Mitchell MD, Polansky JR. Prostaglandin production by human trabecular meshwork cells: *in vitro* inhibition by dexamethasone. *Invest Ophthalmol Vis Sci* 1983; 24: 1541–1545.
29. Chauhan MK., Yenamandra J. Management of glaucoma: effective drug delivery via niosomes, *J Drug deliv therap* 2016; 6(6), 48-53.
30. Schuman JS. Spectral domain optical coherence tomography for glaucoma (an AOS thesis). *Trans Am Ophthalmol Soc* 2008; 106: 426-58.
31. Krupin T, Liebmann JM, Greenfield DS, Ritch R, Gardiner S. Low-pressure glaucoma study group. A randomized trial of brimonidine versus timolol in preserving visual function: results from the low-pressure glaucoma treatment study. *Am J Ophthalmol* 2011; 151: 671-81.
32. Helen V Danesh-Meyer. Neuroprotection in glaucoma: recent and future directions. *Curr Opin Ophthalmol* 2011; 22: 78-86.
33. Caprioli J, Coleman AL. Intraocular pressure fluctuation a risk factor for visual field progression at low intraocular pressures in the advanced glaucoma intervention study. *Ophthalmology* 2008; 115: 1123-9.
34. Coleman AL, Miglior S. Risk factors for glaucoma onset and progression. *Surv Ophthalmol* 2008; 53 (Suppl 1): S3-10.
35. Orzalesi N, Rossetti L, Bottoli A, Fogagnolo P. Comparison of the effects of latanoprost, travoprost, and bimatoprost on circadian intraocular pressure in patients with glaucoma or ocular hypertension. *Ophthalmology* 2006; 113: 239-46.
36. Evans DW, Hosking SL, Gherghel D, Bartlett JD. Contrast. Sensitivity improves after brimonidine therapy in primary open angle glaucoma: a case for neuroprotection. *Br J Ophthalmol* 2003; 87: 1463-5.
37. Klink T, Praetorius S, Leippi S, Klink J, Grehn FJ. Diurnal and nocturnal intraocular pressure fluctuations after trabeculectomy. *Ophthalmologica* 2012; 227:160-5.
38. Guo L, Cordeiro MF. Assessment of neuroprotection in the 36. Retina with DARC. *Prog Brain Res* 2008; 173: 437-50.
39. Woodward DF, Gil DW. The inflow and outflow of anti-glaucoma drugs. *Trends Pharmacol Sci* 2004; 25:238.
40. Schwartz K, Budenz D. Current management of glaucoma. *Curr. Opin. Ophthalmol.* 2004, 15:119.
41. Osborne NN, Wood JP, Cupido A, Melena J, Chidlow G. Topical flunarizine reduces IOP and protects the retina against ischemia-excitotoxicity. *Invest Ophthalmol. Vis. Sci* 2002; 43:1456.
42. Chong ZZ, SH Lin, JQ Kang, K. Maiese. Erythropoietin prevents early and late neuronal demise through modulation of Akt1 and induction of caspase 1, 3 and 8. *J. Neurosci* 2003; Res. 71:659.
43. Coleman A, Miglior S. Risk factors for glaucoma onset and progression. *Survey of Ophthalmology* 2008; 53: S3-10.
44. Wittenborn J, Rein D. Cost-effectiveness of glaucoma interventions in Barbados and Ghana. *Optometry and Vision Science* 2011; 88(1): 155-163.



Cite this article-

Oyeniran Taiwo Opeyemi. Glaucoma: secrets of silent thief of vision- a review. *Universal Journal of Pharmaceutical Research* 2017; 2(3): 26-30.