



Available online on 15.11.2020 at <http://ujpr.org>
Universal Journal of Pharmaceutical Research
 An International Peer Reviewed Journal



Open access to Pharmaceutical research
 This is an open access article distributed under the terms of the Creative Commons Attribution-NonCommercial Share Alike 4.0 License which permits unrestricted non commercial use,

provided the original work is properly cited

Volume 5, Issue 5, 2020



RESEARCH ARTICLE

RADIOGRAPHIC ASSESSMENT OF THE COURSE AND VISIBILITY OF THE MANDIBULAR CANAL BY PANORAMIC RADIOGRAPHY

Nashwan Yahya A Al-Shamahy¹ , Al-Kasem Mohammed Abbas² , Hassan Abdulwahab Al-Shamahy³ , Ameen Abdullah Yahya Al-Akwa⁴ , Khaled M Al-Ghaffari² , Ammar M Al-Mortada² , Mohammed A Al-labani⁴

¹Medicine Department, Faculty of Medicine and Health Sciences, Sana'a University, Republic of Yemen.

²Department of Maxillo-Facial, Faculty of Dentistry, Sana'a University, Republic of Yemen.

³Department of Basic Sciences, Faculty of Dentistry, Sana'a University, Republic of Yemen.

⁴Orthodontics, Pedodontics and Prevention Department Faculty of Dentistry, Sana'a University, Yemen.

ABSTRACT

Background and Objectives: The mandibular canal is a canal inside the mandible that contains the inferior alveolar artery, the inferior alveolar nerve and the inferior alveolar vein. The anatomy and variations of the human mandible are very important for planning various surgical measures such as extraction of the third molar, dental implants and mandibular reconstruction. This study was conducted to determine the frequency of the different courses of the mandibular canal and to investigate the visibility of the mandibular canal by panoramic radiography, among a sample of Yemeni adults.

Subjects and Methods: A retrospective cross-sectional study was conducted in Sana'a city on a sample of Yemeni adults. The study consisted of panoramic radiographs of 928 patients; the number of males was 340 (36.6%) and 588 females (63.4%). The mandibular canal course, as shown in the panoramic radiographs, was classified into four types: elliptical, linear, turning curves and spoon-shaped. The visibility of this canal from the first to the third molar region was assessed through visual determination of whether the lower canal was clearly visible, possibly visible, or invisible.

Results: Elliptical curves were the most observed along the mandibular canal course at 62.2% of the total, followed by the linear curve (24.8%) while the lower rate curve spoon (7.9%) and the turning curve (5.2%). There were no statistically considerable differences between the distribution of the mandibular canal courses between males and females except in the spoon curve where the ratio was 10.8% in males versus 6.1% in females ($p < 0.05$). The percentage of clearly visible mandibular canals was the highest among the spoon-shaped curves (49.9% in the first molar, 63% in the second, 78.1% in the third molar) and the lowest among the linear curves (10.9% in the first, 18.7% in the second and 33.5% in the third molar). On panoramic radiographs, the invisible mandibular canals are found in 198 (21.3%) of the examined sites in the first molar region, in 85 (11%) in the second molar region, and in only 6 (0.64%) in the third molar region.

Conclusion: It was observed that elliptical curves along the path of the mandibular canal were the most present, while a decrease in the ratio of the two types of spoon curve and turning curve was observed. It was found that spoon curve was significantly more common among males than females. It was also found that the visibility of mandibular canal is fewer in the first molar region than in the third molar region.

Keywords: Inferior Alveolar, Mandible, Nerve, Panoramic, Radiography.

Article Info: Received 28 August 2020; Revised 1 October; Accepted 4 November, Available online 15 November 2020



Cite this article-

Al-Shamahy NYA, Abbas Al-Kasem M, Al-Shamahy HA, Al-Akwa AAY, Al-Ghaffari KM, Al-Mortada AM, Al-labani MA. Radiographic assessment of the course and visibility of the mandibular canal by panoramic radiography. Universal Journal of Pharmaceutical Research 2020; 5(5):17-20.

DOI: <https://doi.org/10.22270/ujpr.v5i5.481>

Address for Correspondence:

Dr. Hassan Abdul Wahab Al-Shamahy, Department of Basic Sciences, Faculty of Dentistry, Sana'a University, Republic of Yemen, Tel: +967-770299847, E-mail: shmahe@yemen.net.ye

INTRODUCTION

Inside the mandible is the mandibular canal, which is a canal that contains the inferior alveolar artery, the inferior alveolar vein and the inferior alveolar nerve. It runs obliquely down and forward to the branch, then

forward laterally to the body, where it is placed under the alveoli and communicates with it all through small openings. On reaching the incisive teeth, it turns back to connect with the mental foramen, giving rise to a small canal known as the mandibular incisive canal, which extends into the cavities containing the incisor

teeth¹. The mandibular canal is fairly close to the tops of the second molar in 50% of the radiographs. In 40% the canal is distant from the root apices, and in only 10% of the radiographs, the root crests appeared to penetrate the canal. In root canal treatment of the second molar, care must be taken to extend the perforator expander or root canal filling material because there is a potential risk of injury to the inferior alveolar nerve¹⁻⁴. The mandibular canal is an important milestone to consider before performing any posterior mandibular surgery²⁻⁴. The precise location of the mandibular canal can be provided by radiological diagnosis before surgery and therefore prevent complications during any surgical procedures⁵. The mandibular canal pathway has been investigated in several studies, and frequent anatomical differences have been found in the intrabony course of the inferior alveolar nerve⁶⁻⁸. Moreover, the radial profile of the mandibular canal can be alterable⁹. The mandibular canal visibility may vary significantly¹⁰⁻¹². Wadu *et al.*, discovered that in an adequate number of cases, the

radiopaque boundaries are disrupted in radiographs, and it is invisible in some other cases. The mandibular canal typically consists of a thin trabecular bone including many circumferential spaces, and there is a fine layer of cortical bone in just a few of the mandibles^{13,14}. Recently, Ozturk and colleagues' study¹⁵ and Liu colleagues¹⁶ classified the mandibular canal pathway into linear, spoon-shaped, elliptic, and turning curve types (Figure 1).

In panoramas, the mandibular canal is usually observed as a definite radiopaque area, lined with a radiopaque superior and inferior boundaries⁵. Understanding the anatomical contrast of the pathway and the visibility of the mandibular canal will be helpful in planning treatment for procedures concerning the posterior mandible¹⁵. This study was conducted to determine the frequency of the different courses of the mandibular canal and to investigate the visibility of the mandibular canal by panoramic radiography, among a sample of Yemeni adults.

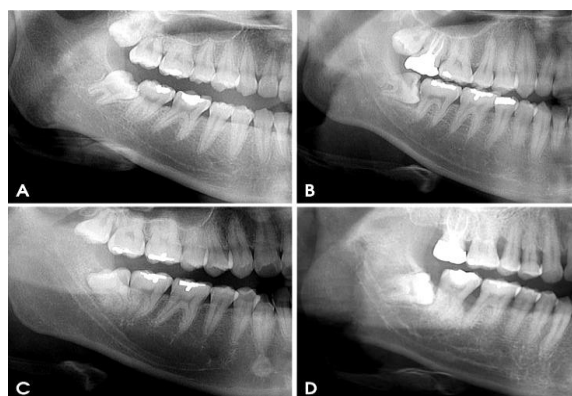


Figure 1: Classifications of the course of the mandibular canal on panoramic radiographs: A- Linear curve, the canal curve is approximately a straight line; B- Elliptic curve, the curve is approximately symmetrical; C- Spoon-shaped curve, the canal has an approximate spoon shape that is similar to an asymmetric elliptic arc; and D-Turning curve, the course is unsmooth and has a turning point¹⁶.

SUBJECTS AND METHODS

The samples in this retrospective study were randomly assigned from patients who visited Ammar Dental Clinics and undertaken panoramic radiography in 2019, up to September 2020. The panoramic radiograph was done as part of the clinical diagnostic process for various causes, as extraction of the third molar and implant placement and or, orthodontic treatment planning. The number of subjects was 588 females and 340 males, with a mean age of 27.3 years and the age range was 20-58 years. Patients with mandibular disease were excluded from the study. Using Proline XC panoramic radiographs were taken for all. These images were carefully examined by the first investigator. The mandibular canal course was classified, as in the published research by Liu *et al.*,¹⁶ where they classified them into four types: elliptic, linear turning curves and spoon-shaped (Figure 1¹⁶). Mandibular canal vision was assessed by visually decisive whether the maxillary canal is obviously visible, possibly visible, or invisible on panoramic

radiographs. Wilcoxon's ranking test was used using online calculators. The Wilcoxon signed-rank test was used using online calculators to recognize statistically significant differences in the visibility of the mandibular canal between the right and the left sides. The Wilcoxon signed-rank test is a non-parametric statistical hypothesis test utilized to contrast two related samples, matching samples, or repeated measurements on a single sample to measure whether the ranks of the norm population differ (i.e. it is a paired difference test). To visualize this duct according to the course of the canal and the difference in visibility in the three mandibular regions, the Kruskal Wallis test was used. A *p* value of less than 0.05 was considered to indicate a statistically significant difference.

Ethical approval

Ethical approval was taken from the Medical Research and Ethics Committee of the Faculty of Medicine & Health Sciences at Sana'a University. All data, including patient identification and X-rays, were kept confidential.

RESULTS

Elliptical curves (Figure 1-B) were the most observed along the mandibular canal course at 62.2% of the total, followed by the linear curve (Figure 1-A) (24.8%) while the lower rate curve spoon (Figure 1-C) (7.9%) and the turning curve (Figure 1-D) (5.2%). There were no statistically significant differences between the distribution of the mandibular canal courses between males and females except in the spoon curve where the ratio was 10.8% in males versus 6.1%

in females ($p < 0.05$). The percentage of clearly visible mandibular canals was the highest among the spoon-shaped curves (49.9% in the first molar, 63% in the second, 78.1% in the third molar) and the lowest among the linear curves (10.9% in the first, 18.7% in the second and 33.5% in the third molar). In panoramic radiographs, invisible mandibular canals were found in 198 (21.3%) of the examined sites in the first molar region, in 85 (11%) in the second molar region, and in only 6 (0.64%) in the third molar region.

Table 1: Frequency of the course of the mandibular canal on panoramic radiographs.

	Linear curve		Elliptic curve		Spoon curve		Turning curve		Total	
	N	%	N	%	N	%	N	%	N	%
Sex										
Male	73	21.5	211	62.1	37	10.8*	19	5.6	340	36.6
Female	157	26.7	366	62.2	36	6.1*	29	4.9	588	63.4
Total	230	24.8	577	62.2	73	7.9	48	5.2	928	100

Table 2: Relationship between the course and the visibility of the mandibular canal on panoramic radiographs.

		Linear curve		Elliptic curve		Spoon curve		Turning curve		Total	
		N	%	N	%	N	%	N	%	N	%
First molar region	Visibility of mandibular canal										
	Invisible	61	26.5	121	17.3	9	12.3	7	14.5	198	21.3
	Probably visible	144	62.6	399	69.2	29	39.7	33	68.8	605	65.2
	Clearly visible	25	10.9	57	9.9	35	47.9	8	16.7	125	13.5
Second molar region	Invisible	30	13	49	8.5	0	0	6	12.5	85	9.2
	Probably visible	157	68.2	443	76.8	27	37	37	77.1	664	71.6
	Clearly visible	43	18.7	85	14.7	46	63	5	10.4	179	19.3
	Total	230	100	577	100	73	100	48	100	928	100
Third molar region	Invisible	5	2.2	1	0.17	0	0	0	0.0	6	0.64
	Probably visible	148	64.3	292	50.6	16	21.9	30	62.5	486	52.4
	Clearly visible	77	33.5	284	49.2	57	78.1	18	37.5	436	47
	Total	230	100	577	100	73	100	48	100	928	100

DISCUSSION

In this study, the mandibular canal course was examined using panoramic radiographs, the canal visibility was assessed, and current results illustrated the contrast and visualization of the canal course. Kieser JA *et al.*, Bertl *et al.*, and Heasman^{7,8,17} classified the mandibular canal course according to vertical locations inside the mandible, such as high, low and intermediate locations. In a study by Heasman¹⁷ using 96 normal films of the dry mandible, it showed that the majority (68%) of the inferior canals passed along an intermediate pathway¹⁷. Ozturk *et al.*, in 2012¹⁵ restricted classification to the canal's course in the mandibular body: catenary-like configuration (51.1%), straight projection (12.2%), and progressive descent from posterior to anterior (36.7%). Also, Ozturk and colleagues' study¹⁵ classified the mandibular canal pathway into spoon-shaped, linear, elliptic, and turning curve types, similar to the study conducted 3 years earlier by Liu *et al.*,¹⁶. The linear curve (24.8%) in the current study was completely different from the straight projection (12.2%) observed by Ozturk *et al.*, in 2012, and the other curves were not similar to their findings¹⁵. In the study by Liu *et al.*,¹⁶ elliptic curves (48.5%) were the most frequent, and spoon-shaped curves (29.3%) were the subsequently most frequent pathway. The most common pathway

found in the current study was the elliptical curve (62.2%). In the study conducted by Jung and Cho in Korea in 2014¹⁸, elliptical curves (64.7%) were the most common, followed by linear curves (22.9%) and spoon curves (6.9%). This result is nearly similar to the current study in which the elliptic curve was 62.2%, followed by the linear curves (24.8%) and the spoon-shaped curves (7.9%). These results indicated that in Yemeni patients there is more space for implant placement, because the elliptical and spatula curves can provide more space for implant placement than the linear curves¹⁸. In the current study, invisible mandibular canals were discovered in 198 (21.3%) of the examined sites in the first molar region, in 85 (11%) in the second molar region, and in only 6 (0.64%) in the third molar region. This finding is consistent with the fact that the visibility of the mandibular canal may differ between patients and between different areas of the lower jaw as described by Oliveira Santos *et al.*,². The current incidence of invisible mandibular canals (21.3%) was lower than that reported by Klinge *et al.*,¹⁹ as the mandibular canal were not visible in 36.1% of the panoramic radiographs. Current study rate (21.3%) is also lower than that of Naitoh *et al.*,²⁰ who reported that in panoramic images, the canal was completely invisible. While current study rate was roughly similar to that reported by Jung and Cho¹⁸ in that the mandibular canal was not invisible in 22.7% of the sites examined

in the first molar region on panoramic radiographs. Additionally, Lindh *et al.*,²¹ in Sweden accounted that the mandibular canal of the specimen cadavers was obviously visible in 25% of the panoramic radiographs. In this study, on the panoramic radiographs, the mandibular canal was obviously visible in 13.5% of the examined positions in the first molar region, 19.3% of the positions examined in the second molar region and 47% of the sites inspected in the third molar region. Imaging of the mandibular canal wall on the panoramic images was linked to the bone density in the alveolar region²⁰. Decreased visibility of the mandibular canal wall on a panoramic radiograph may reveal decreased integrity of the mandibular canal wall and reduced bone trabeculation. The percentages of clearly visible mandibular canals were highest in spoon-shaped curves. The current study result is comparable to that reported by Jung and Cho¹⁸. What's more the current study results showed that visibility of the mandibular canal in the third molar region was better than that in the first molar region (Table 2). This result is similar to that reported previously¹⁸⁻²¹.

CONCLUSION

In conclusion the elliptical curves along the path of the mandibular canal were the most present, while a decrease in the ratio of the two types of spoon curve and turning curve was observed. It was found that spoon curve was significantly more common among males than females. It was also found that the visibility of this canal is less in the first molar region than in the third molar region, that's mean the visibility of the mandibular canal increased in more distal regions of the canal.

AUTHOR'S CONTRIBUTION

This research work is part of a research work under the direction of Al-Kasem Mohammed Abbas. The panoramic radiography images were carefully examined by Nashwan Yahya Al-Shamahy, the professor of radiology, with the help of other authors. All authors assisted with editing the manuscript.

ACKNOWLEDGMENTS

The authors would like to acknowledge Ammar Dental Clinics, Sana'a, Yemen which supported this work.

CONFLICT OF INTEREST

No conflict of interest associated with this work.

REFERENCES

- Greenstein G, Cavallaro J, Tarnow D. Practical application of anatomy the dental implant surgeon. *J Perio* 2008; 11: 837-839. <https://doi.org/10.1902/jop.2008.080086>
- Oliveira-Santos C, Capelozza AL, Dezzoti MS, *et al.* Visibility of the mandibular canal on CBCT cross-sectional images. *J Appl Oral Sci* 2011; 19: 240-3. <https://doi.org/10.1590/S1678-77572011000300011>
- Escoda-Francoli J, Canalda-Sahli C, Soler A, *et al.* Inferior alveolar nerve damage because of overextended endodontic material: a problem of sealer cement biocompatibility? *J Endod* 2007; 33: 1484-9. <https://doi.org/10.1016/j.joen.2007.09.003>
- Tsuji Y, Muto T, Kawakami J, Takeda S. Computed tomographic analysis of the position and course of the mandibular canal: relevance to the sagittal split ramus osteotomy. *Int J Oral Maxillofac Surg* 2005; 34: 243-6. <https://doi.org/10.1016/j.ijom.2004.06.001>
- Kamrun N, Tetsumura A, Nomura Y, *et al.* Visualization of the superior and inferior borders of the mandibular canal: a comparative study using digital panoramic radiographs and cross-sectional computed tomography images. *Oral Surg Oral Med Oral Pathol Oral Radiol* 2013; 115: 550-7. <https://doi.org/10.1016/j.oooo.2013.01.001>
- Worthington P. Injury to the inferior alveolar nerve during implant placement: a formula for protection of the patient and clinician. *Int J Oral Maxillofac Implants* 2004; 19: 731-4. PMID: 15508990
- Kieser JA, Paulin M, Law B. Intrabony course of the inferior alveolar nerve in the edentulous mandible. *Clin Anat* 2004; 17: 107-11. <https://doi.org/10.1002/ca.10196>
- Bertl K, Heimel P, Reich KM, Schwarze UY, Ulm C. A histomorphometric analysis of the nature of the mandibular canal in the anterior molar region. *Clin Oral Invest* 2014; 18: 41-7. <https://doi.org/10.1007/s00784-013-0961-z>
- Anderson LC, Kosinski TF, Mentag PJ. A review of the intraosseous course of the nerves of the mandible. *J Oral Implantol* 1991; 17: 394-403. PMID: 1813647
- Carter RB, Keen EN. The intramandibular course of the inferior alveolar nerve. *J Anat* 1971; 108: 433-40.
- Denio D, Torabinejad M, Bakland LK. Anatomical relationship of the mandibular canal to its surrounding structures in mature mandibles. *J Endod* 1992; 18: 161-5. [https://doi.org/10.1016/S0099-2399\(06\)81411-1](https://doi.org/10.1016/S0099-2399(06)81411-1)
- Wadu SG, Penhall B, Townsend GC. Morphological variability of the human inferior alveolar nerve. *Clin Anat* 1997; 10: 82-7. [https://doi.org/10.1002/\(SICI\)1098-2353\(1997\)10:2<82::AID-CA2>3.0.CO;2-V](https://doi.org/10.1002/(SICI)1098-2353(1997)10:2<82::AID-CA2>3.0.CO;2-V)
- Gowgiel JM. The position and course of the mandibular canal. *J Oral Implantol* 1992; 18: 383-5. PMID: 1298823
- Ba,sa O, Dilek OC. Assessment of the risk of perforation of the mandibular canal by implant drill using density and thickness parameters. *Gerodontology* 2011; 28: 213-20. <https://doi.org/10.1111/j.1741-2358.2009.00362.x>
- Ozturk A, Potluri A, Vieira AR. Position and course of the mandibular canal in skulls. *Oral Surg Oral Med Oral Pathol Oral Radiol* 2012; 113: 453-8. <https://doi.org/10.1016/j.tripleo.2011.03.038>
- Liu T, Xia B, Gu Z. Inferior alveolar canal course: a radiographic study. *Clin Oral Implants Res* 2009; 20: 1212-8. <https://doi.org/10.1111/j.1600-0501.2009.01736.x>
- Heasman PA. Variation in the position of the inferior dental canal and its significance to restorative dentistry. *J Dent* 1988; 16: 36-9. [https://doi.org/10.1016/0300-5712\(88\)90102-9](https://doi.org/10.1016/0300-5712(88)90102-9)
- Yun-Hoa Jung Yun-Hoa, Cho Bong-Hae. Radiographic evaluation of the course and visibility of the mandibular canal. *Imaging Sci Dent* 2014; 44: 273-8. <https://doi.org/10.5624/isd.2014.44.4.273>
- Klinge B, Petersson A, Maly P. Location of the mandibular canal: comparison of macroscopic findings, conventional radiography, and computed tomography. *Int J Oral Maxillofac Implants* 1989; 4: 327-32. PMID: 2639861
- Naitoh M, Katsumata A, Kubota Y, Hayashi M, Arijji E. Relationship between cancellous bone density and mandibular canal depiction. *Implant Dent* 2009; 18: 112-8. <https://doi.org/10.1097/ID.0b013e318198da7e>
- Lindh C, Petersson A, Klinge B. Measurements of distances related to the mandibular canal in radiographs. *Clin Oral Implants Res* 1995; 6: 96-103. <https://doi.org/10.1034/j.1600-0501.1995.060205.x>